

**Inhibition of the anticancer effect of vincristine sulphate on a canine transmissible venereal tumour (TVTc) by nutritional supplementation:**

**A case report**

**Inibição do efeito anticancerígeno do sulfato de vincristina sobre o tumor transmissível canino (TVTc) provocada por suplementação nutricional:**

**Um estudo de caso**

**Inhibición del efecto anticancerígeno del sulfato de vincristina sobre el tumor transmisible canino (TVTc) provocada por suplementación**

**nutricional: Un estudio de caso**

Ligia Chagas-Martinich<sup>1</sup>, Aline Coelho de Freitas<sup>1</sup>

e Cláudio Baptista de Carvalho<sup>2</sup>

**Summary**

The present study shows the case of a patient carrying a cutaneous canine transmissible venereal tumor refractory to treatment with vincristine sulphate (VS). The initial unsuccessful treatment involved five sessions with VS and parenteral nutritional supplementation to control body weight loss. It was followed by treatment cycles in which just VS was administered, leading to significant reduction of the neoplasm after the first session and total regression after three additional sessions. The remissive effect can be explained by the removal of arginine and methionine, amino acids present in the nutritional solution, which may influence a number of tumorigenic processes.

Key words: tumor growth, arginine, methionine, angiogenesis, nitric oxide

**Resumo**

O presente estudo relata o caso de um canino portador de tumor venéreo transmissível cutâneo, refratário ao tratamento com sulfato de vincristina (VS). O procedimento inicial envolveu cinco sessões com VS associadas à suplementação nutricional parenteral contendo vitaminas e aminoácidos para controlar a perda de peso corporal. Os ciclos de tratamento adicionais envolveram apenas a administração de VS, levando à redução significativa

---

1 VM, MSc.

2 VM, MSc, DSc, Senior of Small Animal Clinician from Universidade Estadual do Norte Fluminense Darcy Ribeiro (UENF).

do tumor após a primeira sessão, e regressão total após três sessões adicionais. O efeito remissivo pode ser explicado pela remoção de arginina e metionina, aminoácidos presentes na solução nutritiva, que podem influenciar um número de processos oncogênicos.

Palavras-chave: crescimento tumoral, arginina, metionina, angiogênese, óxido nítrico.

### **Resumen**

El presente estudio muestra el caso de un paciente portador de un tumor cutáneo venéreo transmisible canino refractario al tratamiento con sulfato de vincristina (VS). El procedimiento inicial consistió en cinco sesiones con VS y suplementación nutricional parenteral, conteniendo vitaminas y aminoácidos, para controlar la pérdida de peso corporal. El procedimiento fue seguido por ciclos de tratamiento en que fue administrado apenas VS, llevando a la reducción significativa del tumor después de la primera sesión y regresión total después de tres sesiones adicionales. El efecto remissivo puede ser explicado por la eliminación de arginina y metionina, aminoácidos presentes en la solución nutritiva, que pueden influenciar un número de procesos oncogénicos.

Palabras clave: crecimiento tumoral, arginina, metionina, angiogénesis, óxido nítrico.

### **Introduction**

One of the consequences of tumoral malignancy is a gradual loss of the patient's weight, a condition that may deteriorate to the state of caquexia<sup>1,2</sup>. The clinic state may still get worse by the toxicity that the eventual administration of anticancer drugs might produce<sup>1,2</sup>. Therefore, besides controlling the tumor development, one of the goals of the treatment of the oncological

patient is to prevent or to recover its weight loss, providing an appropriate nutritional supply. The subject is complex, for one, the patient may present metabolic alterations that limit anabolism in healthy tissues, and secondly, an even larger factor is because of the risks of nutrients promoting the growth of tumoral cells<sup>4</sup>. The tumoral growth induction may rise from unspecific factors such as an

increase in energetic supplementation as well as the delivery of biochemical signals directly involved in cellular proliferation or in processes that promote it, like an increase in blood flux to the tumor<sup>4</sup>. All these considerations have led, alternatively, to suggest strategies of *food restriction* for the oncological patient, which is in line with epidemiologic data showing less incidences of cancer in human populations adopting specific diets<sup>3</sup>.

The present communication presents the case of a patient carrying a canine transmissible venereal tumor (TVTc) or canine transmissible sarcoma, whose anticancer treatment was successful just after the removal of nutritional supplementation. TVTc is a contagious neoplasm localized mainly on the external genitalia of male and female dogs that occurs mostly in non-castrated free-roaming animals living in tropical and subtropical countries<sup>5-8</sup>. TVTc varies from a small nodule (5 mm) to a large mass (>10 cm), is firm but friable and during its rapid growth acquires a bright red aspect because of extensive vascularization<sup>5-8</sup>. Its surface frequently

becomes ulcerated and swollen and could become hemorrhagic and infected. The tumor may be single or multiple and regularly is located on the external genitalia, but may occur in adjacent areas and in other forms such as oral, nasal, cutaneous and conjunctival regions<sup>5-8</sup>. TVTc is a histiocytic tumor showing closely packed round cells supported by a fibrovascular stroma<sup>5-8</sup>. The cells exhibit a remarkable aberration in the numbers and morphology of the chromosomes<sup>5-8</sup>. The cells can be experimentally transplanted in allogeneic dogs or other canids by inoculation, The tumour spontaneously regresses following a progressive growth phase which may last over 6 months; During the progression the TVT cells escape the host immune response while the immune system develops defense against the tumor during its regression. This makes TVT an interesting model for studying tumor growth and host immune system interactions<sup>5,6</sup>.

If a TVTc does not relapse spontaneously it should be treated appropriately. While surgical excision, radiation therapy and immunotherapy may be used,

chemotherapy is considered the first choice treatment<sup>5-7</sup>. Vincristine sulphate (0,5 mg/m<sup>2</sup>, IV, once a week during 4 weeks) seems to be very effective, and be excluded only in the case of the neoplasm being present in the ocular form or localized in the central nervous system<sup>5-7</sup>. Normally, total remission is expected after the sixth week of treatment with this drug.

### **The report case**

The patient discussed here was a 7-year-old Chihuahua male. The TVTc diagnostic was based on biopsy<sup>5-7</sup>. The tumor was extensive, covered part of the cervical and thoracic regions and exhibited numerous and large lumps. Consequently, part of the affected skin was ulcerated and with myiasis. The patient looked apathic, anorexic and with low weight. Taken to a private veterinary clinic, the animal was first submitted to a treatment consisting of four weekly sessions in which vincristine sulphate (VS; Oncovin®, Eli Lilly do Brasil, São Paulo, SP, Brazil) 0,75 mg/m<sup>2</sup> was administered IV along with a parenteral nutritional supplementation rich in vitamins and aminoacids (Bionew®,

Vetnil Univet, São Paulo, SP, Brazil). No remission was observed after this treatment and the patient was carried to the Veterinary Hospital of the Universidade Estadual do Norte Fluminense, UENF, under suspicion of resistance to VS and in search of some drug alternative

### **Results and discussion**

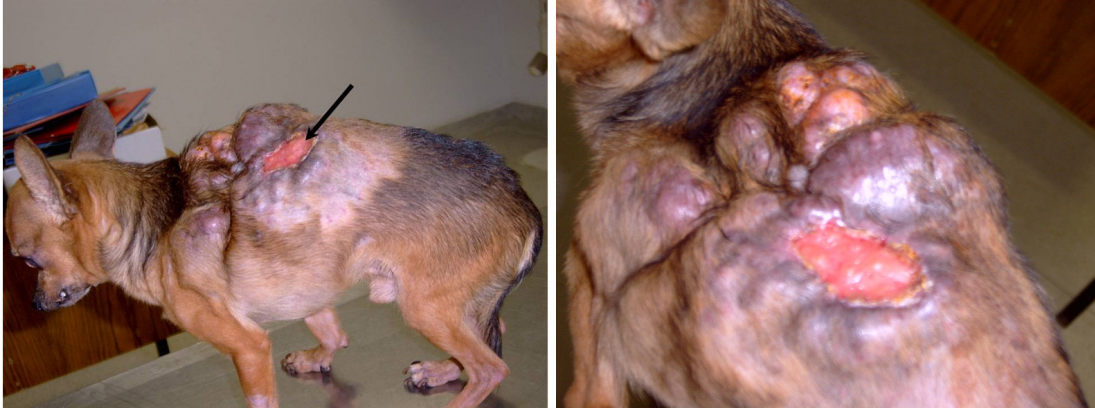
At the Veterinary Hospital one single session was performed following the previous protocol. Minutes after the administration of VS and Bionew® hyperemia was observed on the ulcerated surface. Since the expected result of a VS injection is vasoconstriction and hemorrhage stop<sup>9,10</sup> the localized hyperemia suggested an effect of the nutritional supplement. Accordingly, the next chemotherapeutic session was programmed with the administration of VS alone. A summary of the treatments to which the animal was submitted appears on Table 1. The new schedule involved five weekly administrations of VS starting at the sixth session of chemotherapy. All procedures at the Veterinary Hospital were standard and

followed institutional rules (Figures 1, 2 and 3).

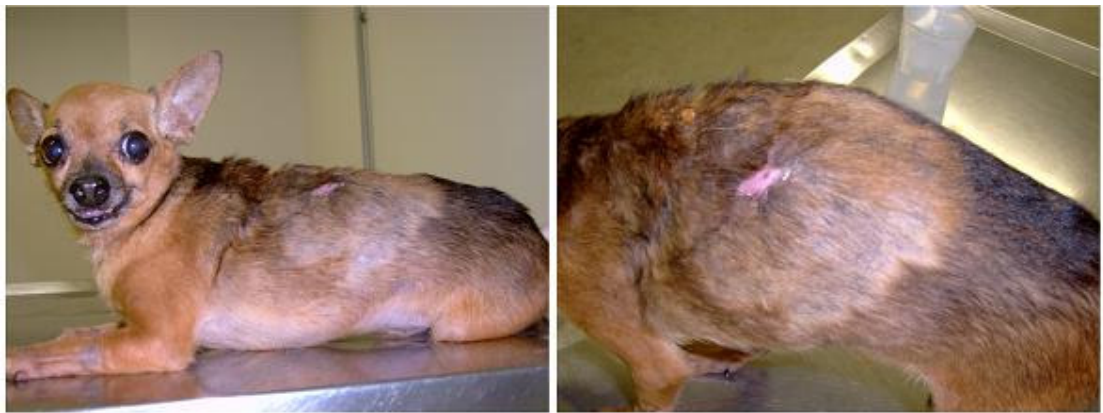Table 1: Canine transmissible veneral tumor. Historical of the patient:

<b>Cemotherapy session</b>	<b>Treatment</b>	<b>Local</b>	<b>Tumor response (*)</b>
1 <sup>st</sup>	VS + Bionew©	Private clinic	No response
2 <sup>nd</sup>	VS + Bionew©	Private clinic	No response
3 <sup>rd</sup>	VS + Bionew©	Private clinic	No response
4 <sup>th</sup>	VS + Bionew©	Private clinic	No response
5 <sup>th</sup>	VS + Bionew©	Veterinary Hospital	No response
6 <sup>th</sup>	VS alone	Veterinary Hospital	Partial regression
7 <sup>th</sup>	VS alone	Veterinary Hospital	Partial regression
8 <sup>th</sup>	VS alone	Veterinary Hospital	Partial regression
9 <sup>th</sup>	VS alone	Veterinary Hospital	Total regression
10 <sup>th</sup>	VS alone	Veterinary Hospital	-

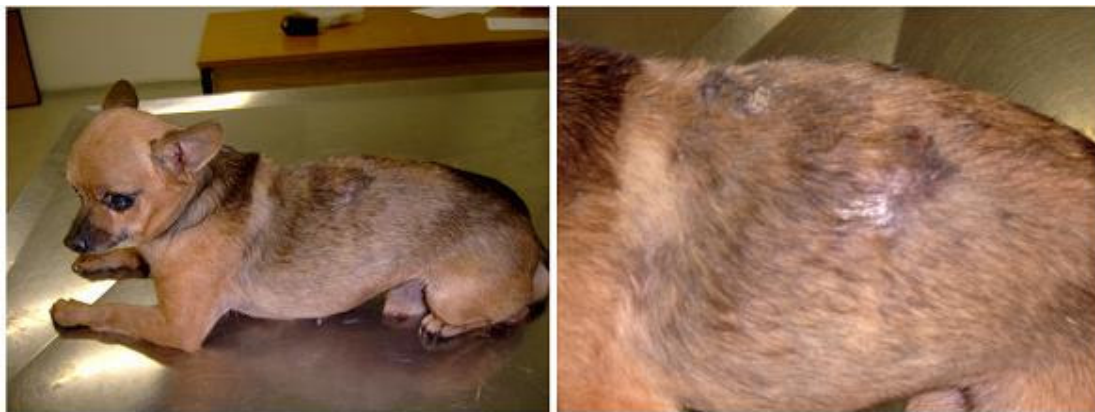VS: Vincristine sulphate. \* Photographs shown in Figure 1 and in Figure 2 were taken just before the beginning of the sessions sixth, eight and tenth respectively.



Figures 1: Canine transmissible veneral tumor. Left and right images show the aspect of the patient just before starting the new protocol. The arrow points to an ulcerated region in which hiperemia was observed just after the administration of both VS and Bionew® in previous sessions. After injecting VS alone no increase was observed on the irrigation of the lesion place and one week later a tumoral remission of approximately 50% was observed.



**Figures 2:** Canine transmissible veneral tumor. The views illustrate the patient one week after the second chemotherapeutic. A 50% reduction of the tumour was observed after the first session and two additional sessions at weekly intervals led to total remission, a result in agreement with the expected and well known effect of VS on TVTc.



Figures 3: A fifth and final administration of VS was practiced as a preventative measure.

The result strongly suggests that the parenteral supplementary nutrition included on the first five treatment sessions promoted the tumoral development thus interfering with the effect of VS. Also, the rapid irrigation increase of the ulcerated region observed after the single VS and Bionew® administration at the Veterinary Hospital (sixth session) is compatible with a vasodilating effect that could be explained by the synthesis of nitric oxide (NO)<sup>10,11</sup> carried out by tumoral cells from the precursor arginine<sup>11,12</sup>, one of the aminoacids present in the nutritional supplement. In the present case, 40 mg of L-arginine chloride diluted in 2 ml were administered to the patient during the first five sessions of chemotherapy. Delayed and long-

term processes promoted by NO, like angiogenesis stimulation<sup>10,12</sup> could be responsible of the tumoral progression observed in this case. The role of angiogenesis on tumoral growth and also on metastatic development has been suggested by studies starting on the 60s by Folkman<sup>11,13,14</sup>, and confirmed with the use of anti-angiogenic drugs such as endostatin and thalidomide<sup>13,14</sup>. All this is accord with studies showing that arginine is essential for the growth of neoplasm cells<sup>12</sup> and with the development of new anticancer treatments based on the deprivation of this aminoacid<sup>15,16</sup>. Bionew® also contains N-acetyl methionine and 40 mg of this compound was administered to the patient at every

session in which 2 ml of supplementary nutrition was added. Methionine is an aminoacid essential in animal diets which must be also present in the culture of most of neoplasm cells and diets reducing its availability have been shown effective in the control of tumorigenesis and to increase the efficacy of cytotoxic drugs<sup>17,18</sup>. This suggests that methionine may have also been a causal factor of the limited response of the patient to VS.

## Conclusion

We may conclude that parenteral nutritional supplementation in the present case was an agent that promoted tumoral growth through the action of at least one of its components, the aminoacids arginine and methionine. Currently, this practice on oncological patients is considered with close caution in the Veterinary Hospital at UENF while more studies are emerging on the effect of nutritional components on tumorigenesis as well as on different types of neoplasm cells.

## References

1. Bosaeus I (2008). Nutritional support in multimodal therapy for cancer cachexia. *Supportive care in cancer*, 16: 447-451.
2. Demoor-Goldschmidt C, Raynard B (2009). How can we integrate nutritional support in medical oncology? *Bulletin du Cancer*, 96: 665-675.
3. McCullough ML, Giovannucci EL (2004). Diet and cancer prevention. *Oncogene*, 23: 6349-6364.
4. Sauer, LA, Blask DE, Dauchy RT (2007). Dietary factors and growth and metabolism in experimental tumors. *The Journal of nutritional biochemistry*, 18: 637-649.
5. Das U, Das AK (2000). Review of canine transmissible venereal sarcoma. *Veterinary research communications*, 24: 545-556.
6. Mukaratirwa S, Gruys E (2003). Canine transmissible venereal tumor, cytogenetic origin, immunophenotype, and immunobiology. A review. *The Veterinary Quarterly*, 25: 101-111.

7. Nak D et al (2005). Clinic-pathological study on the effect of vincristine on transmissible venereal tumour in dogs. *Journal of the American Veterinary Medical Association*, 52: 366-370.
8. Rebbeck CA et al (2009). Origins and evolution of a transmissible cancer. *Evolution*, 63: 2340-2349.
9. Gidding CE et al (1999). Vincristine revisited. *Critical Reviews in Oncology/Hematology*, 29: 267-287.
10. Platts SH et al (1999). Alteration of microtubule polymerization modulates arteriolar vasomotor tone. *The American Journal of Physiology*, 277: 100-106.
11. Fukumura D, Kashiwagi S, Jain RK (2006). The role of nitric oxide in tumour progression. *Nature reviews. Cancer*, 6: 521-534.
12. Lind DS (2004). Arginine and cancer. *The Journal of Nutrition*, 134: 2837S-2841.
13. Zetter BR (2008). The scientific contributions of M. Judah Folkman to cancer research. *Nature Reviews. Cancer*, 8: 647-54.
14. Ribatti D (2009). The discovery of antiangiogenic molecules: a historical review. *Current Pharmaceutical Design*, 15: 345-352.
15. Feun L et al (2008). Arginine deprivation as a targeted therapy for cancer. *Current Pharmaceutical Design*, 14: 1049-57.
16. Lam TL et al (2009). Recombinant human arginase inhibits proliferation of human hepatocellular carcinoma by inducing cell cycle arrest. *Cancer Letters*, 277: 91-100.
17. Poirson-Bichat et al (2000). Methionine depletion enhances the antitumoral efficacy of cytotoxic agents in drug-resistant human tumor xenografts. *Clinical cancer research*, 6: 643–653.
18. Durando X et al (2008). Methionine dependency of cancer cells: a new therapeutic approach? *Bulletin du Cancer*, 95: 69-76.

Recebido em: Novembro de 2009

Aceito em: Dezembro de 2009

Publicado em: Dezembro de 2009